



PATIENT

Rosie Kurth

SPECIES

Canine

BREED

Basset Hound

SEX

Female Intact

AGE

1 year

WEIGHT

56lbs

INTERPRETED BY

Maggie Machen
Lamy, DVM, DACVIM
(Cardiology)

IMAGING PERFORMED BY

Sarah Pender, CVT

HOSPITAL NAME

SVS Imaging QC

REFERRING VET

Dr. Neumeister

INVOICE

21377

DATE

10/1/21

PRESENTING CLINICAL SIGNS

History: The referring vet had difficulty with anesthesia. When prepping for OHE; Rosie was put under anesthesia a few weeks ago for spay. They used ketamine/Valium/Ace to induce and maintain on isoflurane. She wasn't breathing great during prep, and they weren't able to get her to a safe level of anesthesia so the procedure was aborted.

-Abnormal PE/Chem/CBC/UA Results: Physical exam revealed juvenile obesity at a weight of 59.2 lbs. Owners have reduced weight 3 lbs.

-Blood pressure: 148/79, mean 111, 132/37, mean 84, 104/61, mean 81mmHg.

RADIOGRAPHIC FINDINGS *NOTE: Images submitted for supplemental cardiac information only.

Possible right-sided cardiomegaly. No obvious evidence of CHF.

ELECTROCARDIOGRAPHIC FINDINGS *Note: Single lead ECGs are evaluated as a rhythm strip.

Morphology/MEA cannot be definitively commented on.

A single lead ECG is available; 25mm/s, 10mm/mV. The average heart rate is 160bpm (range 150-188bpm). The rhythm is sinus in origin, with a p for every QRS complex and vice versa. The P and QRS morphologies are positive. No ectopic beats, pauses or other dysrhythmias observed. ECG diagnosis: Normal sinus rhythm with respiratory variation.

ECHOCARDIOGRAM FINDINGS

2D, m-mode, color flow and doppler imaging is available. Normal mitral valve. No mitral regurgitation with no left atrial dilation. LV diameter with adequate myocardial function. The tricuspid valve appears normal with mild tricuspid regurgitation. Normal right atrial and ventricular diameter and morphology indicating no overt evidence of pulmonary arterial hypertension. The pulmonic and aortic valves are normal in morphology and mobility. Normal pulmonic and aortic outflow velocities with laminar flow. No obvious aortic or pulmonic insufficiency. No pericardial or pleural effusion noted. No obvious cardiac masses.

CARDIAC CHART

CANINE CARDIAC PARAMETERS	MR VMAX (m/s)	TR VMAX (m/s)	LA/AO (Boon method)	LA/AO (Heart Base; Swe)	FS (%)	EF (%)	EPSS (cm)
NORMAL PARAMETER	4.5-5.5	<2.7	1.3	<1.6	28-40	40-100	<0.6
PATIENT	NA	NM	NM	1.2	48	80	0.62
CANINE CARDIAC PARAMETERS	HR (BPM)	AV VMAX (m/s)	PV MAX (m/s)	BODY WEIGHT (kg)	LA 2D short axis Base view (cm)	LVIDd Avg; 2D and m-mode short axis (cm)	LVIDs Avg; 2D and m-mode short axis (cm)
NORMAL PARAMETER	50-100	0.7-1.7	0.7-1.6	BELOW	BELOW	BELOW	BELOW
PATIENT	167	1.5	1.0	25.4	2.6	2.8	1.5
*Normal chamber parameters expressed as a mean value (SD)				3	1.27 (5.3)	2.46 (2.46)	1.36 (5.5)
BODY WEIGHT DEPENDENT PARAMETERS				5	1.40 (4.5)	2.74 (5.2)	1.60 (4.7)
*Note: All measurements based upon multi-modal images and methods. An average value is reported.				10	1.50 (3.8)	3.27 (3.5)	2.06 (3.1)
				15	1.83 (2.0)	3.71 (2.4)	2.43 (2.1)
				20	2.02 (1.9)	4.14 (2.2)	2.80 (2.0)
				25	2.18 (2.4)	4.48 (2.9)	3.10 (2.5)
				30	2.33 (3.3)	4.83 (3.9)	3.39 (3.4)

Adapted from June Boon, Veterinary Echocardiography, 1998
Rishniw M and Hollis NE, J Vet Intern Med 2000; 14:429-435



PATIENT

Rosie Kurth

Hansson et al, Vet Rad and Ultrasound 2002	35	2.48 (4.3)	5.17 (5.0)	3.69 (4.5)
Bonagura et al. Echocardiography: principles of interpretation, Vet Clin North Am 15:1177, 1995	40	2.62 (5.2)	5.48 (6.1)	3.96 (5.4)
	50	2.88 (7.1)	6.07 (8.3)	4.46 (7.4)

SPECIES

Canine

BREED

Basset Hound

SEX

Female Intact

AGE

1 year

WEIGHT

56lbs

INTERPRETED BY

Maggie Machen
Lamy, DVM, DACVIM
(Cardiology)

IMAGING PERFORMED BY

Sarah Pender, CVT

HOSPITAL NAME

SVS Imaging QC

REFERRING VET

Dr. Neumeister

INVOICE

21377

DATE

10/1/21

INTERPRETATION OF THE FINDINGS & FURTHER RECOMMENDATIONS

Overtly normal cardiac dimensions and function, with no obvious congenital defects visualized. A small tricuspid leak is likely physiologic in origin; however, follow up is advised should a murmur be assaulted in the future. These findings would suggest the radiographic findings are a normal variant.

The ECG is unremarkable with a normal sinus tachycardia.

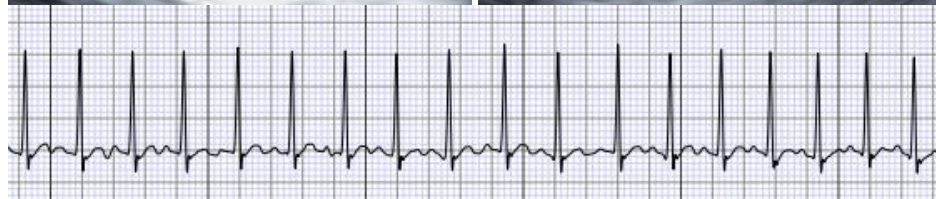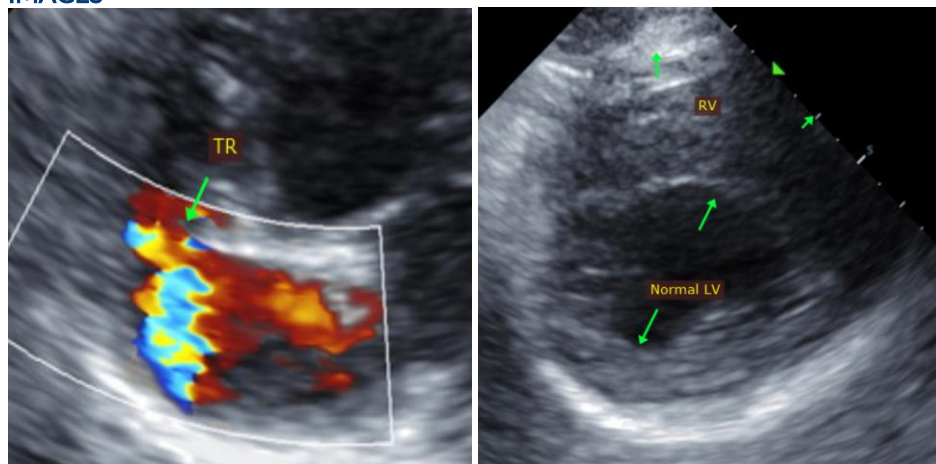
The reported blood pressures are too variable to interpret. Ideally obtain serial measurements in a controlled, low stress environment and continue until the readings plateau within 5mmHg of variability for 3+ readings.

These findings would suggest the anesthetic reaction was non-cardiac in origin. Consider alternative possibilities including a specific drug reaction. Consultation with an Anesthesiologist may be useful prior to proceeding.

Monitor for development of a heart murmur, cough, labored breathing, exercise intolerance or collapse episodes.

A recheck echocardiogram is recommended should a significant murmur develop, or signs of cardiac compromise be noted in the future.

IMAGES





PATIENT

Rosie Kurth

The information and recommendations provided are based on the images presented by the referring veterinarian. No evaluation can be communicated regarding pathology that was not visible in the image/video clips provided.

SPECIES

Canine

Thank you for this referral. This report was generated using transcription software, and minor dictation errors may be present. If the clinical or image interpretation does not parallel your findings or if I can be of any further assistance, please contact me.

BREED

Basset Hound

Maggie Machen Lamy, DVM
Diplomate of the American College of Veterinary Internal Medicine (Cardiology)
info@sonopath.com

SEX

Female Intact

AGE

1 year

WEIGHT

56lbs

INTERPRETED BY

Maggie Machen
Lamy, DVM, DACVIM
(Cardiology)

**IMAGING
PERFORMED BY**

Sarah Pender, CVT

HOSPITAL NAME

SVS Imaging QC

REFERRING VET

Dr. Neumeister

INVOICE

21377

DATE

10/1/21